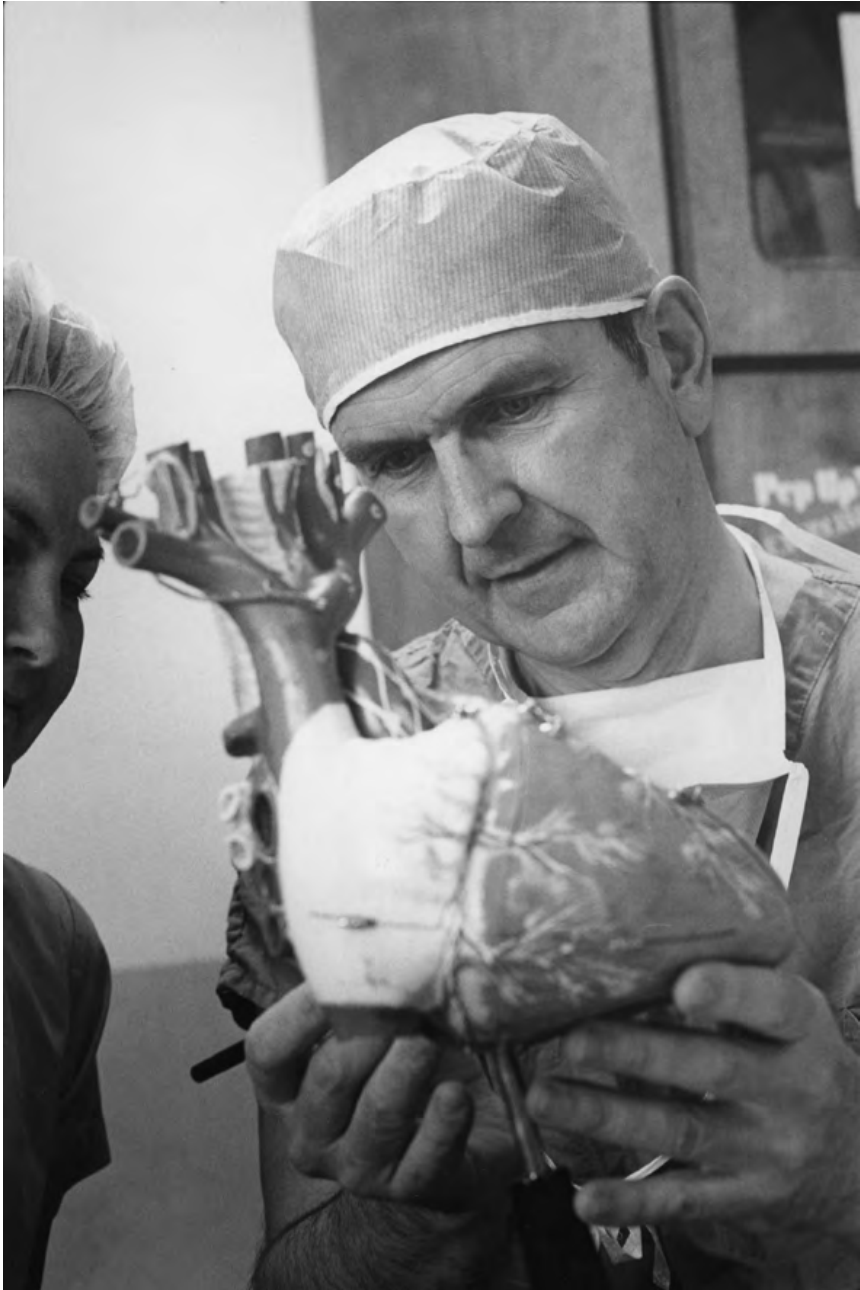

Dr. Russell M. Nelson examines a model of the human heart. As a surgeon, he was instrumental in creating the first heart-lung machine and performed many open-heart operations, including one of the first successful tricuspid valve repairs. Courtesy Church History Library.

Discovering a Surgical First

Russell M. Nelson and Tricuspid Valve Annuloplasty

Austin A. Robinson and Curtis T. Hunter

In an April 2003 general conference address, Elder Russell M. Nelson of the Quorum of the Twelve Apostles recounted an experience of receiving sudden inspiration on how to perform surgery during his medical career. The epiphanic image that came to the young surgeon in 1960 led to the repair of a previously inoperable valve defect in the heart of E. L., a Latter-day Saint stake patriarch. As a novel surgical approach, the case is remarkable. However, Nelson did not publish a report of the experience in the medical literature at the time, and, as a result, its place in surgical history of the twentieth century has not been fully described. The primary purposes of this article are to: (1) document the circumstances surrounding that operation, (2) describe in detail the operative technique, and (3) place the surgery in its proper medical and historical context.

In addition to his public comments on the topic, Nelson has generously supplied additional information to make this publication possible. In exploring the historical and secular context of the experience, this article attempts to foster wider appreciation for an event that carried great surgical as well as personal and spiritual meaning for Nelson. In doing so, we follow the approach of LeRoy S. Wirthlin, whose influential article in this journal first identified nineteenth-century doctor Nathan Smith as the surgeon behind Joseph Smith's boyhood operation.¹ Wirthlin's work illuminated our understanding of Joseph Smith's life story

1. LeRoy S. Wirthlin, "Nathan Smith (1762–1828) Surgical Consultant to Joseph Smith," *BYU Studies* 17, no. 3 (1977): 319–37.

as well as the career of Nathan Smith, who went on to found medical schools at both Dartmouth and Yale.²

Nelson's operation on E. L. is similarly situated at the intersection of faith and medicine. The general conference address provides one of only a few descriptions of the event:³ "During the early pioneering days of surgery of the heart," a stake patriarch from southern Utah

suffered much because of a failing heart. He pleaded for help, thinking that his condition resulted from a damaged but repairable valve in his heart.

Extensive evaluation revealed that he had *two* faulty valves. While one could be helped surgically, the other could not. Thus, an operation was *not* advised. He received this news with deep disappointment.

Subsequent visits ended with the same advice. Finally, in desperation, he spoke to me with considerable emotion: "Dr. Nelson, I have prayed for help and have been directed to you. The Lord will not reveal to me *how* to repair that second valve, but He can reveal it to you. Your mind is so prepared. If you will operate upon me, the Lord will make it known to you what to do. Please perform the operation that *I* need, and pray for the help that *you* need."

His great faith had a profound effect upon me. How could I turn him away again? Following a fervent prayer together, I agreed to try. In preparing for that fateful day, I prayed over and over again, but still did not know what to do for his leaking tricuspid valve. Even as the operation commenced, my assistant asked, "What are you going to do for that?"

I said, "I do not know."

We began the operation. After relieving the obstruction of the first valve, we exposed the second valve. We found it to be intact but so badly dilated that it could no longer function as it should. While examining this valve, a message was distinctly impressed upon my mind: *Reduce*

2. Oliver S. Hayward and Constance E. Putnam, *Improve, Perfect, and Perpetuate: Dr. Nathan Smith and Early American Medical Education* (Hanover, N.H.: University Press of New England, 1998). Wirthlin's work still continues to foster interest and goodwill within the Latter-day Saint and medical communities. One manifestation is the funding of a medical student scholarship by the descendants of Joseph Smith Sr. in honor of Nathan Smith at Dartmouth. See Lucy Schouten, "Race Marks Bicentennial of Surgery That Saved Joseph Smith's Leg," *DeseretNews.com*, August 4, 2013, <http://www.deseretnews.com/article/865584072/Race-marks-bicentennial-of-surgery-that-saved-Joseph-Smiths-leg.html?pg=all>.

3. Russell M. Nelson, "Sweet Power of Prayer," *Ensign* 33, no. 5 (2003): 7–9. Similar reports are given in Russell Nelson, *From Heart to Heart* (Salt Lake City: Nelson, 1979); Spencer J. Condie, *Russell M. Nelson: Father, Surgeon, Apostle* (Salt Lake City: Deseret Book, 2003).

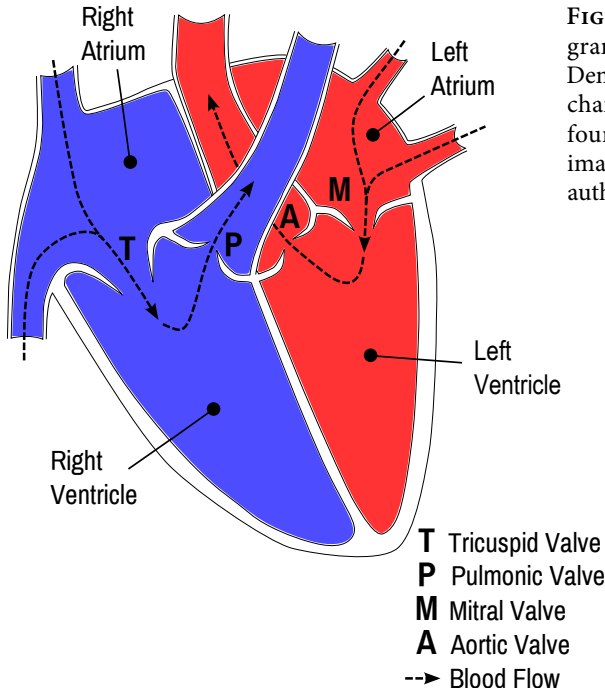


FIGURE 1. Simplified diagram of a healthy heart. Demonstrated are the four chambers, as well as the four cardiac valves. The image was created by the authors.

the circumference of the ring. I announced that message to my assistant. “The valve tissue will be sufficient *if* we can effectively reduce the ring toward its normal size.”

But how? We could not apply a belt as one would use to tighten the waist of oversized trousers. We could not squeeze with a strap as one would cinch a saddle on a horse. Then a picture came vividly to my mind, showing how stitches could be placed—to make a pleat here and a tuck there—to accomplish the desired objective. I still remember that mental image—complete with dotted lines where sutures should be placed. The repair was completed as diagrammed in my mind. We tested the valve and found the leak to be reduced remarkably. My assistant said, “It’s a miracle.”

I responded, “It’s an answer to prayer.”⁴

The Clinical Problem

A brief review of relevant cardiac anatomy and physiology may complement a discussion of the situation faced by Nelson. The heart consists of four chambers divided among two sides, a right and a left (see fig. 1). Each side is composed of a smaller chamber, or atrium, through which blood

4. Nelson, “Sweet Power of Prayer,” 7–8.

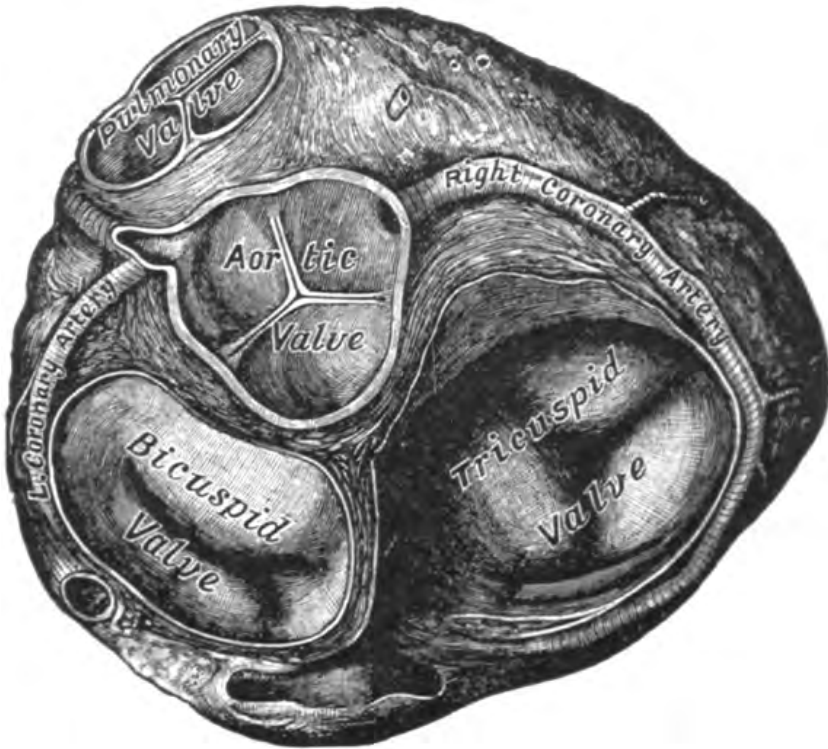

FIGURE 2. Cross-section of the heart. Viewed from above with the atria removed, the four cardiac valves are visualized: tricuspid, pulmonary (pulmonic), aortic, and bicuspid (mitral). From Henry Gray's *Anatomy of the Human Body* (Philadelphia: Lea and Febiger, 1918).

is funneled into a larger ventricle, where the bulk of the pump function is performed. The heart's right side is responsible for circulation of oxygen-poor blood through the lungs for reoxygenation and then back to the left atrium. The left side of the heart, in turn, generates the high pressures necessary to transmit the freshly oxygenated blood to the body and organs.

A system of four valves ensures proper forward flow of blood (see fig. 2). The outflow tracts of the ventricles are capped by valves named for the next circulatory destination: the pulmonic valve in the right, and the aortic valve in the left heart. More important to this case are the two atrio-ventricular valves that divide each atrium from its corresponding ventricle. Between the right atrium and right ventricle lies the tricuspid valve, named for the three leaflets that distinguish it from the bicuspid valve on the left. The bicuspid valve is more commonly known as the mitral valve,

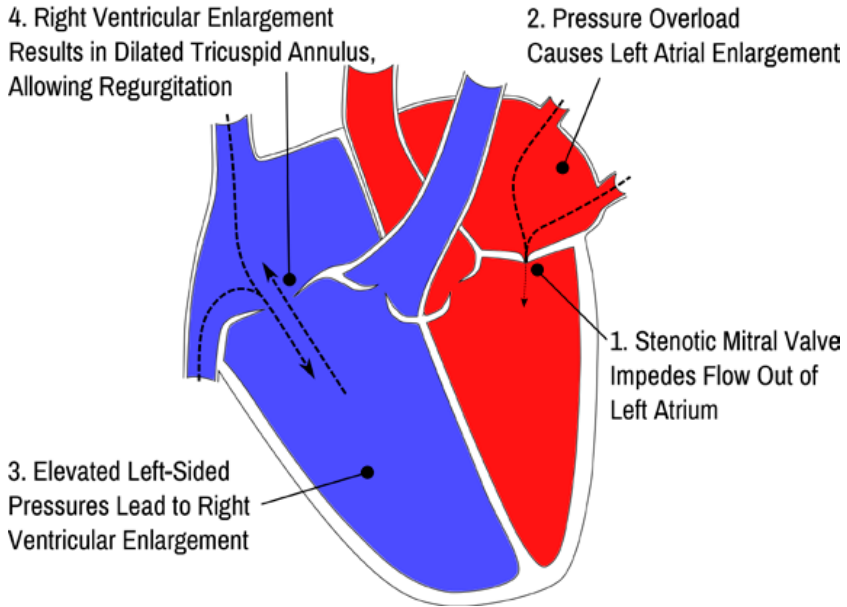


FIGURE 3. Simplified diagram of the patient's diseased heart. Schematic representing the changes resulting in functional tricuspid regurgitation due to mitral stenosis, as experienced by E.L. Outflow obstruction due to mitral stenosis causes pressure overload in the left atrium, resulting in left atrial enlargement and eventually transmission of elevated pressures to the right ventricle. Consequent enlargement of the right ventricle leads to distortion of the tricuspid valve apparatus, misalignment of leaflets, and functional tricuspid regurgitation. The image was created by the authors.

owing to its supposed resemblance to the mitres of Catholic clergy. The mitral and tricuspid valves have the same constituent parts: the valve leaflets are rooted at their base in a fibrous ring, called an annulus, and attached at their apices to bandlike cords, called chordae tendineae. The chordae tendineae connect to strong papillary muscles in the ventricles to prevent valve prolapse during contraction.

There are two general patterns of disease in heart valves—either the valve becomes too tight or too loose. In the first problem, the valve leaflets may become stiffened, impairing their ability to open and allow blood to cross the threshold between chambers. This state is referred to as valvular stenosis. The second condition is a problem with valve closure, where an effective seal fails to form. Such valvular insufficiency, also known as regurgitation, allows retrograde flow of blood that directly opposes the heart's primary pump function. E.L. was afflicted by both

such maladies, one in each of his atrioventricular valves. He had stenosis of his mitral valve that, according to Nelson, resulted from rheumatic fever earlier in life.⁵ This relatively common illness was complicated by severe regurgitation of his tricuspid valve.⁶ It is important to note that these two conditions were not unrelated occurrences, but that one arose as a consequence of the other (see fig. 3).

Mitral valve stenosis provides a functional obstruction to the flow of blood, preventing equalization of pressures between the left atrium and the left ventricle. As a result, less blood flows into the left ventricle with each cardiac cycle, and the pressures in the left atrium rise in proportion to the degree of mitral stenosis.⁷ The result is a cascade of increasing volumes, pressures, and distention backward along the circulatory route. After increased pressures in the left atrium, the next successive complication is elevated hydrostatic pressure in the pulmonary vessels that increases fluid transfer into the airspaces of the lungs, leading to breathlessness. The maladaptive cycle continues in the right ventricle, with rising pressures and, ultimately, enlargement of the chamber itself.⁸ Ventricular dilation causes distortion of the tricuspid valve annulus and misalignment of the valve leaflets.⁹ The net result of this

5. Nelson, "Sweet Hour of Prayer," 8, 9 n. 23.

6. For more information on this complication, see Roy M. Acheson, "The Epidemiology of Acute Rheumatic Fever 1950–1964," *Journal of Chronic Diseases* 18, no. 8 (1965): 723–34, doi:10.1016/0021-9681(65)90016-0.

7. Eugene Braunwald and others, "The Hemodynamics of the Left Side of the Heart as Studied by Simultaneous Left Atrial, Left Ventricular, and Aortic Pressures; Particular Reference to Mitral Stenosis," *Circulation* 12, no. 1 (July 1, 1955): 69–81, doi:10.1161/01.CIR.12.1.69; "ACC/AHA 2006 Guidelines for the Management of Patients with Valvular Heart Disease: Executive Summary: A Report of the American College of Cardiology/American Heart Association Task Force on Practice Guidelines (Writing Committee to Revise the 1998 Guidelines for the Management of Patients with Valvular Heart Disease): Developed in Collaboration with the Society of Cardiovascular Anesthesiologists: Endorsed by the Society for Cardiovascular Angiography and Interventions and the Society of Thoracic Surgeons," *Circulation* 114, no. 5 (August 1, 2006): 450–527, doi:10.1161/CIRCULATIONAHA.106.177303.

8. François Haddad and others, "Right Ventricular Function in Cardiovascular Disease, Part II: Pathophysiology, Clinical Importance, and Management of Right Ventricular Failure," *Circulation* 117, no. 13 (April 1, 2008): 1717–31, doi:10.1161/CIRCULATIONAHA.107.653584.

9. Shahzad G. Raja and Gilles D. Dreyfus, "Basis for Intervention on Functional Tricuspid Regurgitation," *Seminars in Thoracic and Cardiovascular Surgery* 22, no. 1 (2010): 79–83, doi:10.1053/j.semtcvs.2010.05.005.

complex pathophysiology is imprecise valve closure and regurgitant flow of blood backward into the veins of the neck and abdomen with each contraction of the ventricles.

In this manner, E. L.'s mitral valve disease was causing the failure of his tricuspid valve—a situation referred to as functional tricuspid insufficiency. By 1960, surgeons had observed that isolated repair of mitral stenosis without correction of functional tricuspid regurgitation was associated with high perioperative mortality.¹⁰ More recent studies have shown that severe tricuspid regurgitation, whether alone or secondary to left-sided valve disease, is associated with poor quality of life and high mortality.¹¹ Ideally, E. L.'s tricuspid valve could be repaired at the same time as the mitral valve. However, at that time, there was no known way of doing so, and the tricuspid valve's inoperability rendered E. L.'s condition ultimately incurable.

The State of Cardiac Surgery

Nelson aptly describes the era as “the early pioneering days of surgery of the heart.”¹² It was a period of rapid expansion in our repertoire of cardiac surgeries. At the time Nelson was approached by E. L., open-heart surgery was less than a decade old. Prior to that time, operative correction of valvular stenosis was limited and performed blindly with a finger-guided knife, or in some cases, using the finger itself to force open valve commissures in a procedure referred to as “finger fracture commissurotomy.”¹³

10. Jerome Harold Kay, Giuseppe Maselli-Campagna, and Harold K. Tsuji, “Surgical Treatment of Tricuspid Insufficiency,” *Annals of Surgery* 162, no. 1 (1965): 53–58.

11. Jayant Nath, Elyse Foster, and Paul A. Heidenreich, “Impact of Tricuspid Regurgitation on Long-Term Survival,” *Journal of the American College of Cardiology* 43, no. 3 (February 4, 2004): 405–9, doi:10.1016/j.jacc.2003.09.036; Anita Sadeghpour and others, “Impact of Severe Tricuspid Regurgitation on Long Term Survival,” *Research in Cardiovascular Medicine* 2, no. 3 (2013): 121–26, doi:10.5812/cardiovascmed.10686; Rick A. Nishimura and others, “2014 AHA/ACC Guideline for the Management of Patients with Valvular Heart Disease: A Report of the American College of Cardiology/American Heart Association Task Force on Practice Guidelines,” *Journal of the American College of Cardiology* 63, no. 22 (June 10, 2014): e57–185, doi:10.1016/j.jacc.2014.02.536.

12. Nelson, “Sweet Power of Prayer,” 7.

13. Marco Picichè, ed., *Dawn and Evolution of Cardiac Procedures—Research Avenues in Cardiac Surgery and Interventional Cardiology* (Italia: Springer, 2013),

Such blind surgery precluded more complicated procedures on the heart. Nelson was especially aware of this, having been part of the team that developed the first successful heart-lung bypass machine at the University of Minnesota, work that formed the basis of his PhD dissertation.¹⁴ The technique quickly caught on among surgeons. After its first use in Minnesota in 1951, bypass was successfully employed to support open-heart surgery at Jefferson University Hospital in Philadelphia by May 6, 1953.¹⁵ Upon returning from training at Harvard's Massachusetts General Hospital, Nelson brought the technique to Salt Lake in 1955. His operation in November of that year gave Utah the distinction of being only the third state in the entire country with open-heart surgery capabilities.¹⁶

Surgical Advances for the Mitral and Tricuspid Valves

Cardiopulmonary bypass allowed for the development of the open field, so necessary for more complex cardiac surgical procedures. After initial successes in repairing congenital structural defects, surgeons set their sights on the problem of diseased heart valves. The open field finally allowed surgeons an *in vivo* view of heart valve function and insight into how each of the valve components interacts during the phases of the cardiac cycle. Such intricate understanding of valve physiology had eluded prior researchers who had to rely on autopsy studies of lifeless hearts.¹⁷

<http://www.springer.com/medicine/surgery/book/978-88-470-2399-4>; J. C. Dávila, "The Birth of Intracardiac Surgery: A Semicentennial Tribute (June 10, 1948–1998)," *The Annals of Thoracic Surgery* 65, no. 6 (1998): 1809–20; Dwight E. Harken and others, "The Surgery of Mitral Stenosis: III. Finger-Fracture Valvuloplasty," *Annals of Surgery* 134, no. 4 (1951): 722–41.2013.

14. Russell M. Nelson, "Metabolic Effects of Paracolon Bacteremia," *Annals of Surgery* 134, no. 5 (1951): 885–96; Condie, *Russell M. Nelson*.

15. Clarence Dennis and others, "Development of a Pump-Oxygenator to Replace the Heart and Lungs: An Apparatus Applicable to Human Patients and Application to One Case," *Annals of Surgery* 134, no. 4 (1951): 709–21; J. H. Gibbon, "Application of a Mechanical Heart and Lung Apparatus to Cardiac Surgery," *Minnesota Medicine* 37, no. 3 (1954): 171–85, *passim*.

16. Condie, *Russell M. Nelson*, 132.

17. C. W. Lillehei and others, "Surgical Correction of Pure Mitral Insufficiency by Annuloplasty under Direct Vision," *The Journal-Lancet* 77, no. 11 (1957): 446–49.

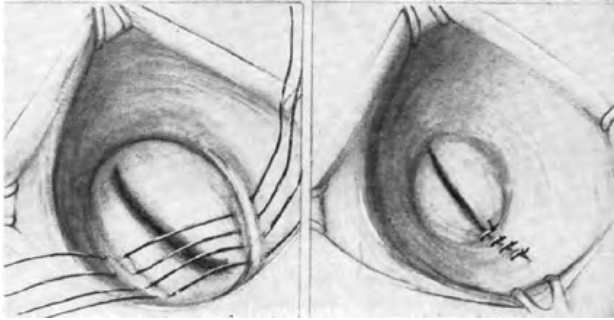


FIGURE 4. Early repair of mitral regurgitation. Merendino's early repair technique for mitral insufficiency, first performed October 1956 and published July 1959. (Merendino and others, "The Open Correction of Rheumatic Mitral Regurgitation and or Stenosis," 11.)

The mitral valve commanded much of the initial attention, and the latter half of the 1950s saw several surgeons develop new procedures for the correction of mitral insufficiency. In 1956, C. Walton Lillehei, one of Nelson's former colleagues at the University of Minnesota, employed cardiopulmonary bypass to directly visualize an incompetent mitral valve and then introduced a method of closing it by suturing into the annulus on each side. Lillehei placed sutures across the incompetent portion of each valve, leaving a residual, functional valve.¹⁸ He termed the procedure mitral valve annuloplasty, applying the suffix *-plasty*, meaning to form or mold.¹⁹ Others devised different surgical solutions, including Geoffrey Wooler at Leeds General Infirmary, H. William Scott at Vanderbilt University, Earle Kay at St. Vincent Hospital in Cleveland, and another cardiac surgeon with a PhD from the University of Minnesota, K. Alvin Merendino (see fig. 4).²⁰

18. Lillehei and others, "Surgical Correction of Pure Mitral Insufficiency," 446–49.

19. Sandra R. Patterson, *Medical Terminology from Greek and Latin* (Troy, N.Y.: Whitston Publishing, 1978), 54.

20. G. H. Wooler and others, "Experiences with the Repair of the Mitral Valve in Mitral Incompetence," *Thorax* 17, no. 1 (1962): 49–57; E. B. Kay and F. S. Cross, "Surgical Treatment of Mitral Insufficiency," *Surgery* 37, no. 5 (1955): 697–706; H. William Scott and others, "Surgical Correction of Mitral Insufficiency under Direct Vision: Report of Clinical Cases," *Annals of Surgery* 147, no. 5 (1958): 625–33; K. Alvin Merendino and others, "The Open Correction of

By the late 1950s, tricuspid valve therapy lagged significantly behind the mitral valve. Few researchers studied the tricuspid valve, and it was “never specifically targeted by any one surgeon during this time period.”²¹ Such inattention was possibly due to the fact that rheumatic fever, one of the most common causes of valvular disease, typically affected left-sided valves, or potentially because valve failure amid the higher pressures of the heart’s left side produced more dramatic clinical pathology. Regardless of the reason, however, it is clear that Nelson did not have the benefit of others’ prior experience as he set out to operate on what has been called “the forgotten valve.”²²

Nelson in His Career

Nelson’s life had brought him into personal acquaintance with the damage to heart valves caused by rheumatic fever. During surgical residency, Nelson and his wife found close friends in Don and Netta Davis, another medical couple in their twenties. Netta developed rheumatic mitral stenosis, which, during their time in Minnesota, progressed into florid heart failure. As he and his young wife watched Netta waste away physically and ultimately succumb to the effects of her valve disease, Nelson resolved to commit his professional career to treating such profound heart disease. The experience was perhaps the pivotal moment in diverting Nelson’s career from general surgery to cardiac surgery.²³

Nelson’s career up through 1960 had afforded him the opportunity of treating such patients, and, by the time he was approached by E. L., Nelson had accumulated some professional experience with rheumatic heart disease. At the time of his operation for the stake patriarch, Nelson had performed seventy-three operations in the open field and a total of sixty mitral valve operations—not insignificant numbers for less than five years in the newest of medical fields.²⁴ However, by today’s standards, his surgical experience would be considered rather limited.

Rheumatic Mitral Regurgitation and or Stenosis,” *Annals of Surgery* 150, no. 1 (1959): 5–22.

21. P. A. Iaizzo and others, eds., *Heart Valves: From Design to Clinical Implantation* (New York: Springer), 91, <http://www.springer.com/biomed/book/978-1-4614-6143-2>.

22. Picichè, *Dawn and Evolution of Cardiac Procedures*, 207.

23. Condie, *Russell M. Nelson*, 107.

24. Russell M. Nelson to authors, “Personal Correspondence—Provided to Editors,” July 10, 2014.

Modern cardiothoracic surgeons typically have already performed three hundred cardiac surgeries when they start their careers after the conclusion of surgical training during residency.²⁵ Furthermore, Nelson's particular work on conditions relevant to E.L.'s case was even more limited. His open-field operations on the mitral valve, the closest surgical correlate to the tricuspid valve, numbered only eight, and he had performed just two repairs of mitral valve insufficiency.²⁶ Nelson was hardly embarking on a routine procedure, even if the mitral valve were his only surgical objective. However, targeting a tricuspid valve defect was venturing entirely into the unknown.

Description of the Procedure

In spite of such inexperience, Nelson knew that without correction of E.L.'s valvular problems, his symptoms would continue to deteriorate and his life expectancy would be limited. He agreed to attempt surgery, and a date of May 24, 1960, was set for the operation. Surgical exploration would confirm Nelson's preoperative diagnosis. The patient indeed had rheumatic mitral stenosis: "On viewing the interior of the heart, first of all with regard to the mitral valve, there was pure mitral stenosis with the valve orifice being about 1 cm. I could get my index fingertip into the orifice down to the end of my fingernail but could get it no further. There was no mitral regurgitation. . . . The valve edge was thickened and rough."²⁷

Nelson first performed mitral valve commissurotomy, breaking adhesions between the mitral leaflets at the commissures and liberating associated structures. After this procedure, he was able to pass two full fingers through the valve and into the left ventricle. Satisfied that the mitral stenosis had been corrected to the point of allowing good valvular function, he turned his attention to the heart's right side and the tricuspid valve. One can imagine the nervous expectancy of opening the right atrium widely to find the severe functional tricuspid regurgitation Nelson had expected.

25. Rafe Connors and others, "Effect of Work-Hour Restriction on Operative Experience in Cardiothoracic Surgical Residency Training," *The Journal of Thoracic and Cardiovascular Surgery* 137, no. 3 (March 2009): 710–13.

26. Nelson, "Personal Correspondence—Provided to Editors."

27. Russell M. Nelson, "Mitral Commissurotomy; Tricuspid Commissurotomy Employing Extracorporeal Circulation," Operative Report, Salt Lake City, LDS Hospital, May 27, 1960.

Findings at the tricuspid valve were those of complete incompetence of this valve. I could thrust all five digits on my right hand through the valve into the right ventricle. I did not think that there had been any valvulitis from rheumatic fever to this valve, as actually the valve leaflets were thin and supple. However, there had been gross dilatation of the annulus of the valve, so that on the right lateral border of the annulus, there was no valve tissue present. With each ventricular systole, there was a total reflux of blood up into the right atrial chamber. . . . There was no tricuspid stenosis whatsoever.²⁸

It was at this moment of considering the problem that Nelson received the critical impression—reduce the circumference of the ring.²⁹ The idea that the valve tissue would be sufficient must have been surprising at the time, given Nelson’s observation that there was “no valve tissue present” at the right lateral annulus.³⁰ Nonetheless, he proceeded to focus on the directive to reduce the annular circumference. The description provided in his general conference address is informative about the options Nelson felt he had available to him: “We could not apply a belt as one would use to tighten the waist of oversized trousers. We could not squeeze with a strap as one would cinch a saddle on a horse.”³¹

Nelson recognized that external constricting ligatures had failed spectacularly before in work on the mitral and aortic valves. Purse-string sutures placed into external heart tissue around incompetent mitral valves eventually tore through the heart’s muscular layer.³² When the eminent surgeon Charles Bailey had attempted a similar approach for aortic valves, the band migrated out of place, sometimes occluding flow through the coronary arteries and causing heart attacks.³³ Belt and strap approaches had been tried before and the outcome was not good. Nelson would have to look to another approach to reverse such gross dilation.

28. Nelson, “Mitral Commissurotomy.”

29. Nelson, “Sweet Power of Prayer,” 8.

30. Nelson, “Mitral Commissurotomy.”

31. Nelson, “Sweet Power of Prayer,” 8.

32. Iaizzo and others, *Heart Valves*, 101.

33. Robert P. Glover and Julio C. Davila, “Surgical Treatment of Mitral Insufficiency by Total Circumferential ‘Purse-String’ Suture of the Mitral Ring,” *Circulation* 15, no. 5 (May 1, 1957): 661–81, doi:10.1161/01.CIR.15.5.661; Iaizzo and others, *Heart Valves*, 101; Charles P. Bailey and William Likoff, “The Surgical Treatment of Aortic Insufficiency,” *Annals of Internal Medicine* 42, no. 2 (February 1, 1955): 388–416, doi:10.7326/0003-4819-42-2-388.

What remained was to directly manipulate the valve annulus, a difficult and complicated approach. Nelson could not replicate what other surgeons had done in the development of mitral valve annuloplasty by reversing methods of mitral stenosis repair, since there existed no analogous procedure for tricuspid stenosis. Furthermore, he could not simply extrapolate mitral valve annuloplasty techniques to the tricuspid valve: The triple-leaflet structure of the tricuspid valve meant that there were three commissures, compared to the dual commissures of the mitral valve, as well as a distinct three-dimensional contour with a unique process of distortion compared to mitral valve insufficiency.³⁴

Rather than replicate a prior process, Nelson operated according to the image in his mind. His immediate postoperative dictation (see fig. 5) describes the procedure:

It became evident that there was valve tissue that would function, were it in approximation, one leaflet to another, and so this was allowed to happen by constriction of the diameter of the annulus by mattress suture plication of the annulus of the valve. This was accomplished by placing . . . mattress sutures of heavy silk through the annulus. . . . Each suture was placed through a pillow of ivalon sponge as a reinforcing buttress into which the stitch might rest. After placement of the third stitch . . . we had completely abolished all of the leak and still left an opening of the tricuspid valve through which my second and third fingers might easily pass, with room to spare.³⁵

Nelson placed strong sutures into the tricuspid valve annulus across from each other, which he used to plicate—or fold—the annulus. In doing so, he brought the anterior and posterior annulus together. He placed two sutures at the commissure between the anterior and posterior leaflets at the valve’s lateral edge and another set of sutures at the commissure between the anterior and septal leaflets, along the opposite border. In drawing together the valve at its edges, he constricted the annulus enough to restore leaflet closure. The operation had transformed the configuration of the tricuspid valve (see fig. 6). More importantly, its function was altered as well: when Nelson allowed blood to

34. Renan Sukmawan and others, “Geometric Changes of Tricuspid Valve Tenting in Tricuspid Regurgitation Secondary to Pulmonary Hypertension Quantified by Novel System with Transthoracic Real-Time 3-Dimensional Echocardiography,” *Journal of the American Society of Echocardiography* 20, no. 5 (May 1, 2007): 470–76, doi:10.1016/j.echo.2006.10.001.

35. Nelson, “Mitral Commissurotomy.”

enter the right ventricle, it was pumped forward without any evident regurgitation into the right atrium. The tricuspid insufficiency was gone. The operation was a success.

The significance of the moment would not have been lost on the operating room staff. Nelson's first assistant likely gave voice to the feelings of all present, including the scrub nurse and two other surgical residents, with his spontaneous exclamation, "It's a miracle."³⁶ For his part, Nelson seemed taken by the experience as well. In his postoperative dictation, he was unsure of even the name of the procedure, opting for the term tricuspid commissurorrhaphy, using the suffix *-rrhaphy* to denote suturing at the commissures.³⁷ Future surgeons would adopt a different term to maintain consistency of nomenclature among valves. It would be called tricuspid valve annuloplasty.

Significant Elements

Our modern vantage point yields interesting insights on Nelson's tricuspid valve annuloplasty and its place in surgical history. Novel procedures are often preceded by careful experimentation before they see the daylight of clinical practice. C. Walton Lillehei and colleagues performed research on animal heart valves for several years before they attempted their first mitral valve annuloplasty in a human patient.³⁸ Nelson and his research team in Minnesota had done the same with the pump oxygenator on dogs before it was used to sustain a hospital patient.³⁹ In fact, Nelson's own research focused on infectious complications of pump oxygenator use that had to be resolved before a trial in humans would ever be feasible.⁴⁰ By contrast, Nelson attempted a first-ever tricuspid valve annuloplasty without preparatory research of any kind. Nelson's on-the-spot tricuspid valve repair contrasts sharply with his own prior medical experience and the standard practice of his surgical contemporaries.

Given such circumstances, the technique he employed seems all the more remarkable. For example, Nelson did not justify his reason for starting at the valve's right lateral border, but later studies would validate this approach. Functional tricuspid annular dilation is now understood

36. Nelson, "Sweet Power of Prayer," 8.

37. Patterson, *Medical Terminology from Greek and Latin*, 115.

38. Lillehei and others, "Surgical Correction of Pure Mitral Insufficiency," 446.

39. Dennis and others, "Development of a Pump-Oxygenator," 714.

40. Nelson, "Metabolic Effects of Paracolon Bacteremia," 885.

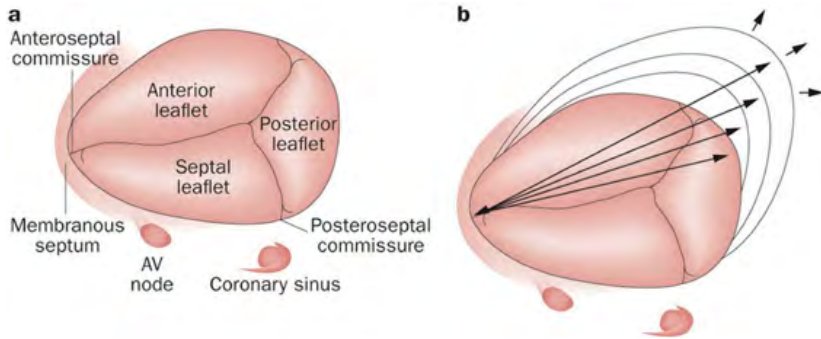


FIGURE 7. Asymmetric tricuspid annular dilation. Image demonstrating a healthy tricuspid valve (left), and the pattern of asymmetric dilation of the tricuspid annulus in functional tricuspid insufficiency (right). Note that dilation occurs in two directions: laterally (represented by rightward arrow) as well as anteriorly (upward arrow). Reprinted by permission from Macmillan Publishers, Ltd.: Shinn and Schaff, “Evidence-Based Surgical Management of Acquired Tricuspid Valve Disease,” *Nature Reviews Cardiology* (2013).

to progress in an asymmetric fashion, with selective lengthening of the segments corresponding to the anterior and posterior leaflets; the septal leaflet, by contrast, remains relatively unchanged (see fig. 7).⁴¹ The junction of the anterior and posterior leaflets, located near the right lateral extreme of the annulus, is therefore an ideal target for annular reduction.

Nelson’s tricuspid annuloplasty was notable for more than just its technique. New cardiac surgical procedures of that era often proved dangerous as they were first being implemented. Charles Bailey, the man behind the first correction of mitral stenosis, experienced four consecutive fatalities before achieving success with his fifth attempt at mitral valve commissurotomy.⁴² The first patient sustained by cardiopulmonary bypass also died of surgical complications.⁴³ Even after the first successful operation by Gibbon in 1953, the next four attempts at

41. Gilles D. Dreyfus and others, “Secondary Tricuspid Regurgitation or Dilatation: Which Should Be the Criteria for Surgical Repair?” *The Annals of Thoracic Surgery* 79, no. 1 (2005): 127–32, doi:10.1016/j.athoracsur.2004.06.057.

42. Charles Philamore Bailey, “The Surgical Treatment of Mitral Stenosis (Mitral Commissurotomy),” *CHEST Journal* 15, no. 4 (April 1, 1949): 377–93, doi:10.1378/chest.15.4.377.

43. Dennis and others, “Development of a Pump-Oxygenator,” 719.

open-heart surgery ended in patient deaths.⁴⁴ In November 1958, a year and a half before Nelson's surgery, a group of Philadelphia surgeons reported an 80 percent fatality rate in their attempts at open repair of the mitral valve.⁴⁵ That E. L. not only survived but did well, experiencing symptomatic relief and living for "many more years" after Nelson's foray into tricuspid valve repair, is fortunate and quite remarkable.⁴⁶

It is important to note that, despite the obvious innovation involved in Nelson's annuloplasty, he certainly drew on elements of his surgical experience in order to perform the surgery. For example, Nelson knew that annular plication was a possibility only because of his familiarity with colleagues' work on other valves, particularly the mitral valve. His choice of materials, too, would have been guided by experience. Use of heavy silk to suture into the annulus and Ivalon sponge reinforcements to prevent annular tearing were undoubtedly informed by Lillehei's use of these same items in his work on mitral valve annuloplasty.⁴⁷ Nelson was, after all, a heart surgeon, and it was this rare combination of knowledge and inspiration that allowed him to perform the surgery. E. L. had known this, having sought him out because his mind was "so prepared."⁴⁸ Novel though it was, Nelson's tricuspid annuloplasty was no *ex nihilo* operation.

Nelson was not the only surgeon attempting to correct tricuspid insufficiency at the time. In 1965, his close personal friend and colleague at the University of Southern California, Jerome Kay, published his own repair technique for tricuspid insufficiency (see timeline in fig. 8).⁴⁹ Unknown to Nelson, Jerome Kay had been developing his technique of tricuspid valve annuloplasty since 1960 (see fig. 9). Kay performed his first case in March of that year, only two months before Nelson had done the same in Utah. Because Kay waited five years to publish his results, Nelson had no knowledge of the Californian's work on tricuspid valves in 1960. As Newton and Leibniz had done with calculus centuries

44. Picichè, *Dawn and Evolution of Cardiac Procedures*, 314.

45. E. B. Kay and others, "Surgical Treatment of Mitral Insufficiency," *The Journal of Thoracic Surgery* 36, no. 5 (November 1958): 677–90.

46. Nelson, "Sweet Power of Prayer," 8.

47. Lillehei and others, "Surgical Correction of Pure Mitral Insufficiency," 449.

48. Nelson, "Sweet Power of Prayer," 8.

49. Kay, Maselli-Campagna, and Tsuji, "Surgical Treatment of Tricuspid Insufficiency," 53.

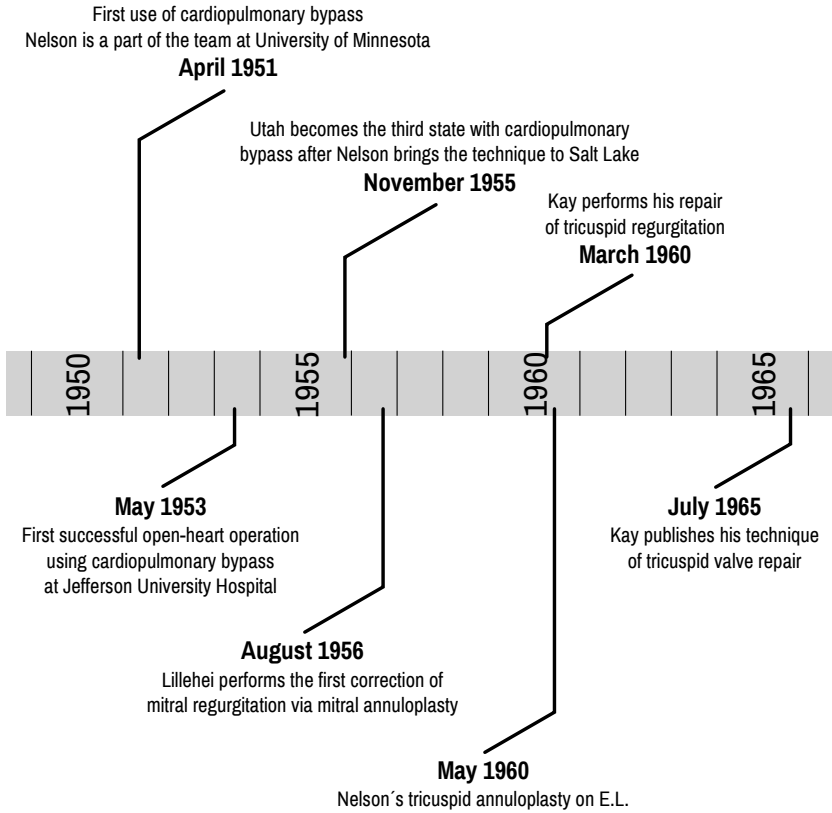


FIGURE 8. Timeline of selected surgical milestones.

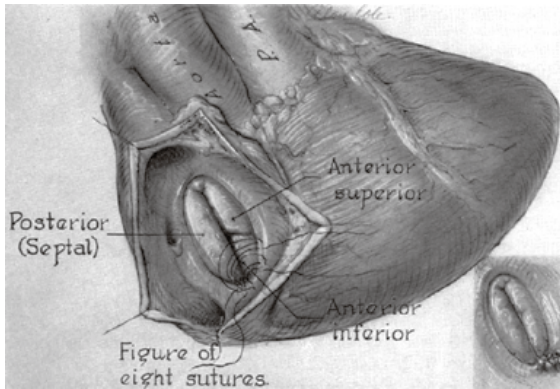


FIGURE 9. Kay's tricuspid valve repair (Kay, Maselli-Campagna, and Tsuji, "Surgical Treatment of Tricuspid Insufficiency," 54). The Kay repair involved surgical obliteration of the posterior leaflet, effectively converting a tricuspid valve to a bicuspid. Note that the names for the leaflets have been standardized since Kay's original labels: "Anterior superior" = anterior; "Posterior (Septal)" = septal; "Anterior inferior" = posterior.

earlier, Nelson and Kay had independently and concurrently developed the first-ever surgical repair for tricuspid regurgitation.

The Kay annuloplasty is similar in several respects to Nelson's: both operations involve annular plication via lateral placement of sutures. However, Kay omitted medial plication and focused only on the lateral annulus around the posterior leaflet. Instead of Nelson's sutures centered over the anteroposterior commissure, Kay placed several sutures across the posterior leaflet which, when tightened, effectively obliterated this leaflet. The net result was exclusion of the posterior leaflet and effective bicuspidization of the tricuspid valve.

Over the ensuing years, physicians would discover that one of the major problems of the Kay technique was that it prevented annular dilation only at the valve's lateral border and did not address the problem of dilation along the anterior annulus.⁵⁰ If anterior dilation continued, the repair would eventually fail. The Nelson annuloplasty technique, by contrast, incorporated elements to reinforce against this problem. Nelson's lateral sutures reversed dilation along the posterior leaflet in a similar manner to the Kay annuloplasty. Meanwhile their combination with plication sutures at the antero-septal commissure would have buttressed against anterior dilation. In ways beyond what Nelson could have appreciated at the time, he was reversing regurgitation by targeting the vectors of distortion that had caused the problem.

Ahead of its time though it was, Nelson's technique was not widely disseminated outside his immediate circle of affiliates, and the Kay annuloplasty became known as the first repair technique for tricuspid insufficiency after its publication in 1965.⁵¹ Others would propose modifications,⁵² but the annular plication techniques of Nelson and Kay

50. Picichè, *Dawn and Evolution of Cardiac Procedures*, 208.

51. Picichè, *Dawn and Evolution of Cardiac Procedures*, 208; Sapan S. Desai and Andrew J. Lodge, "Surgery of the Tricuspid and Pulmonary Valves," in *Valvular Heart Disease*, ed. Andrew Wang and Thomas M. Bashore, Contemporary Cardiology (Humana Press, 2009), 337, http://link.springer.com/chapter/10.1007/978-1-59745-411-7_15; Jan Dominik and Pavel Zacek, *Heart Valve Surgery: An Illustrated Guide*, 318, <http://www.springer.com/medicine/surgery/book/978-3-642-12205-7>.

52. Pierre Grondin at the Montreal Heart Institute, for example, proposed an interesting hybrid technique that combined Kay's bicuspidization with antero-septal plication sutures like Nelson. See P. Grondin and others, "The Tricuspid Valve: A Surgical Challenge," *The Journal of Thoracic and Cardiovascular Surgery* 53, no. 1 (January 1967): 7–20.

remained the primary method of correcting tricuspid insufficiency until 1972, when Norberto De Vega published a technique involving semi-circular suture placement circumferentially *along* the annulus over the anterior and posterior leaflets.⁵³ The field has continued to evolve, and modern strategies rely on use of commercially available synthetic rigid or semirigid rings to reshape a dilated annulus, rather than sutures alone.⁵⁴

Nelson's Technique Never Published

One may ask why Nelson never published a report of the new procedure. Despite maintaining detailed surgical records of the case that corroborate the event, Nelson was prevented by several practical barriers from publishing the new repair. By 1960, the standard for describing new surgical techniques typically involved reporting a series of patients. Lillehei included four patients in his initial description of mitral valve annuloplasty, but subsequent reports would involve greater numbers: Wooler and Earle Kay reported thirty-eight and twenty-eight cases, respectively.⁵⁵ The series of twenty tricuspid valve annuloplasties published by Jerome Kay had taken Kay and two other collaborators nearly five years to accumulate.⁵⁶ It would have required Nelson, working as a single surgeon in a smaller population center than southern California, much longer to accrue a series of surgical cases large enough to report in the literature.

Nelson also had no special professional focus on functional tricuspid regurgitation, and in the year 1960 alone he was engaged in several other surgical and academic projects. He had presciently begun to concentrate on the increasing problem of coronary artery atherosclerosis. That same year he joined a small group of surgeons at the leading edge

53. N. G. De Vega, "Selective, Adjustable and Permanent Annuloplasty. An Original Technic for the Treatment of Tricuspid Insufficiency," *Revista Española De Cardiología* 25, no. 6 (1972): 555–56.

54. Sung Ho Shinn and Hartzell V. Schaff, "Evidence-Based Surgical Management of Acquired Tricuspid Valve Disease," *Nature Reviews Cardiology* 10, no. 4 (2013): 190–203, doi:10.1038/nrcardio.2013.5; Desai and Lodge, "Surgery of the Tricuspid and Pulmonary Valves," 339.

55. Lillehei and others, "Surgical Correction of Pure Mitral Insufficiency," 449; Wooler and others, "Experiences with the Repair of the Mitral Valve," 49; Kay and others, "Surgical Treatment of Mitral Insufficiency," 677.

56. Kay, Maselli-Campagna, and Tsuji, "Surgical Treatment of Tricuspid Insufficiency," 56.

of the field when he performed coronary arteriography and coronary thromboendarterectomy.⁵⁷ In 1960, he also prepared or published several academic articles on cardiovascular physiology, including on anti-arrhythmic medications and hormonal regulation of vascular tone.⁵⁸ All this came in addition to his busy clinical workload, a substantial educational and administrative burden as the director of Utah's only cardiothoracic surgical training program, and ecclesiastical responsibilities that included serving as a counselor in his ward bishopric and as a Temple Square missionary every Thursday afternoon.⁵⁹ In 1960, Nelson was not well positioned to embark on a case series of tricuspid valve repair.

Conclusion

From Netta Davis to E. L., Nelson's first tricuspid annuloplasty carried a rare confluence of personal, professional, and spiritual significance for the young surgeon. It was the realization of a personal commitment he had made while watching a dying friend that came as a uniquely tangible answer to prayer. The operative repair that resulted was a first-of-its-kind correction for a previously untreatable and potentially fatal defect in the heart's tricuspid valve. More than just a novel approach, however, Nelson's annuloplasty technique would prove a remarkably effective solution to the problem of tricuspid regurgitation, one that would anticipate problems with contemporary approaches years before they were appreciated by the surgical community at large.

In the intervening five decades medical science has progressed considerably, introducing new synthetic materials and repair strategies for the correction of tricuspid insufficiency. However, as a group of modern

57. Picichè, *Dawn and Evolution of Cardiac Procedures*, 148, 266; Nelson, *From Heart to Heart*, 318.

58. E. Englert and others, "Effects of Changing Hepatic Blood Flow on 17-Hydroxycorticosteroid Metabolism in Dogs," *Surgery* 47 (June 1960): 982–86; R. M. Nelson and others, "The Anti-Arrhythmia Properties of the Tranquilizer Drugs," *Surgical Forum* 10 (1960): 525–27; R. M. Nelson, J. W. Henry, and J. H. Lyman, "Influence of 1-Norepinephrine on Renal Blood Flow, Renal Vascular Resistance, and Urine Flow in Hemorrhagic Shock," *Surgery* 50 (July 1961): 115–25.

59. Condie, *Russell M. Nelson*, 142.

surgeons recently noted,⁶⁰ the message impressed on the mind of a scrubbed-in, nervous surgeon as he peered into a dilated right atrium in 1960 has remained a fundamental principle in surgical correction of tricuspid insufficiency through the present day: reduce the circumference of the ring.

Austin A. Robinson is a resident in the Department of Internal Medicine at Yale University School of Medicine and Yale–New Haven Hospital. He received his MD from the UCLA School of Medicine in 2013.

Curtis T. Hunter is Associate Clinical Professor of Surgery in the Division of Cardiothoracic Surgery at UCLA as well as Co-Director of Cardiac Surgery at St. John's Health Center in Santa Monica, California. After earning his MD from the University of Utah School of Medicine, he completed a residency in general surgery at the University of North Carolina Hospitals, followed by a fellowship in Thoracic Surgery at Boston University Medical Center.

The authors would like to thank the following:

Jeffrey Robinson, Hal Boyd, Rachel Robinson, and Robyn Robinson for invaluable help in sharpening the focus of this work and bringing clarity to the discussion.

Lynsey Ekema for lending her talents to the creation of the beautiful image of Nelson's operative technique.

The Cushing/Whitney Medical Library at Yale for assistance in obtaining access to mid-twentieth-century surgical publications.

Elder Russell M. Nelson and Wendy Larson for generosity of time and resources essential to understanding the context and details of Nelson's operation.

60. P. M. Correia, G. F. Coutinho, and M. J. Antunes, "Tricuspid Valve: A Valve Not to Be Forgotten," *European Society of Cardiology E-Journal of Cardiology Practice* 11, no. 19 (April 23, 2013), <http://www.escardio.org/communities/councils/ccp/e-journal/volume11/Pages/prophylactic-treatment-tricuspid-regurgitation.aspx#.VO4jeEs8oeV>.